

Pre-Contrast Imaging of the Area At Risk in Acute Myocardial Infarction: T2 yields higher contrast than T1 MRI

A. H. Aletras¹, P. Kellman¹, L-Y. Hsu¹, D. Groves¹, R. F. Hoyt Jr. ², and A. E. Arai¹

¹Laboratory of Cardiac Energetics, National Heart, Lung and Blood Institute, Bethesda, Maryland, United States, ²Office of the Scientific Director, National Heart, Lung and Blood Institute, Bethesda, Maryland, United States

Introduction: The area at risk (AAR) of infarction is the hypoperfused myocardial bed during coronary occlusion. The edematous AAR can be delineated in-vivo by T2 MRI and can be used in conjunction with delayed contrast enhancement to calculate myocardial salvage. T1 MRI has been recently used to image the edema associated with acute myocardial infarction.

Objectives: We hypothesized that, due to the intrinsic T1 and T2 associated with myocardial edema, higher contrast between the AAR and normal myocardium would be measured with pre-gadolinium T2 MRI than with pre-gadolinium T1 MRI. We also hypothesized that this would also be true for contrast between the infarct and peri-infarct zones within the AAR.

Methods: MRI was performed 3 days after LAD occlusion-reperfusion in 13 dogs. The AAR was defined as having less than 50% blood flow by microspheres. The infarcted territory was defined by post-gadolinium delayed enhancement. In order to obtain tissue contrast measurements independent of pulse sequence used, T2 and T1 maps were computed from pre-gadolinium MRI with T2-prepared SSFP (14 TE's of 16-280ms) and with IR-GRE (10 TIs of 71-900ms) respectively. Both pulse sequences were calibrated on phantoms with known T1 and T2. Contrast, i.e. the ability to differentiate between two types of tissue, was defined as the ratio of the difference between average (T1 or T2) values over their standard deviation.

Results: The microsphere blood flow during occlusion (depicting the AAR), the delayed contrast enhanced MRI (depicting the non-transmural infarct) and corresponding pre-gadolinium T1 and T2 maps are shown in Figure 1. Within the area at risk (dark zones by microspheres) the T1 map depicts elevated T1 values (red area) relative to the remote myocardium (green area). It is not easy to differentiate peri-infarct from infarct zones with T1 in this animal. While elevated T2 values are seen in the T2 map within the AAR relative to remote myocardium, it is also possible to delineate two zones within the AAR itself: the infarct zone (yellow area) and the peri-infarct zone (red area).

Figure 2 shows the T2 values (left chart) and T1 values (right chart) for the three zones for all animals. The average T2 value of the infarct, the peri-infarct zone and remote myocardium were 72 ± 2 , 57 ± 2 and 46 ± 3 ms respectively. The corresponding average T1 values were 1020 ± 18 , 972 ± 18 and 879 ± 13 . Contrast between the different zones is shown in the Table. In all cases, T2 provided better contrast (range: 35-262%).

Discussion: Our in-vivo results suggest that T2 MRI can yield better contrast than T1 MRI for differentiating infarct, peri-infarct and remote myocardium. These results do not reflect limitations set by a particular pulse sequence but rather by the physiology itself. These results are based on the intrinsic T1 and T2 changes as a result of different water content, water mobility and interactions with the lattice within the three regions. Given the in-vivo T1 and T2 values reported above, even simple T1 and T2 exponential calculations of the available signal show that contrast is better in T2-weighted images. This is despite the fact that the absolute signal is higher in T1-weighted images. This is visible in Figure 1 where, despite the fact that less noise is seen in the T1 map than in the T2 map, there is clearly less contrast between the infarct and peri-infarct zones in the T1 map compared to the T2 map.

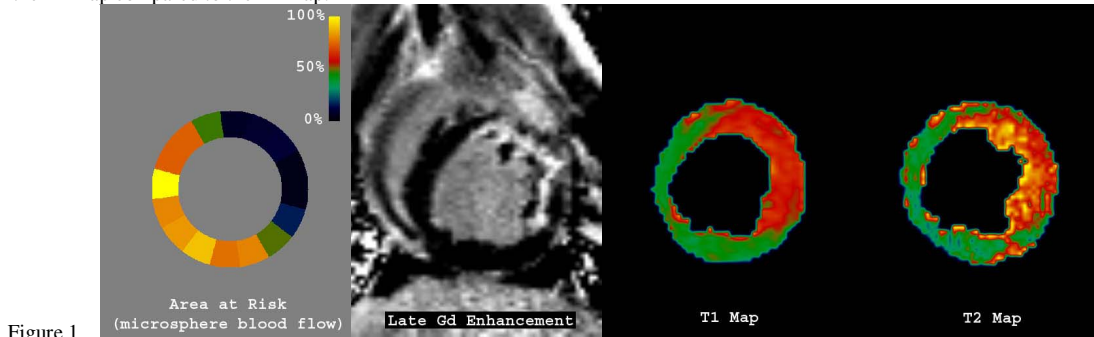


Figure 1

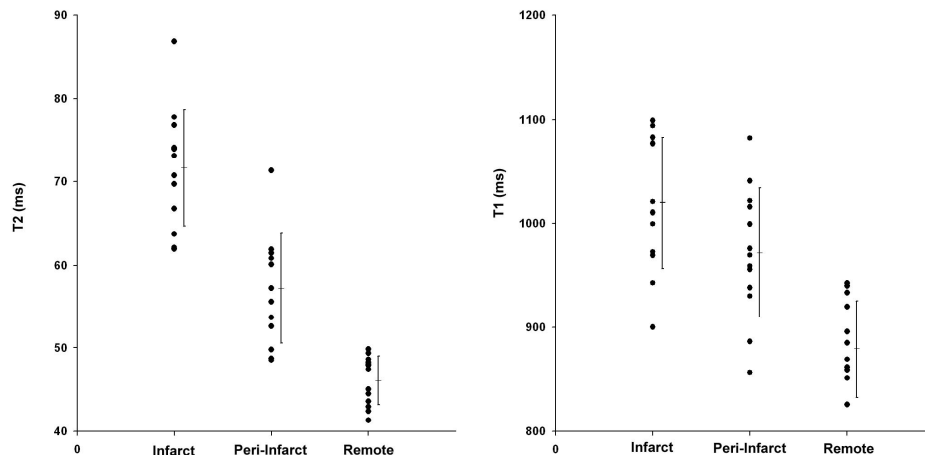


Figure 2

Infarct vs. Remote		Infarct vs. Peri-infarct		Peri-infarct vs. Remote	
T2	T1	T2	T1	T2	T1
5.2	2.6	2.1	0.8	2.3	1.7